

# **Section 1**

## **LECTURE**

### **Overview of Embryology**

### Overview of Embryology of the Digestive Tract

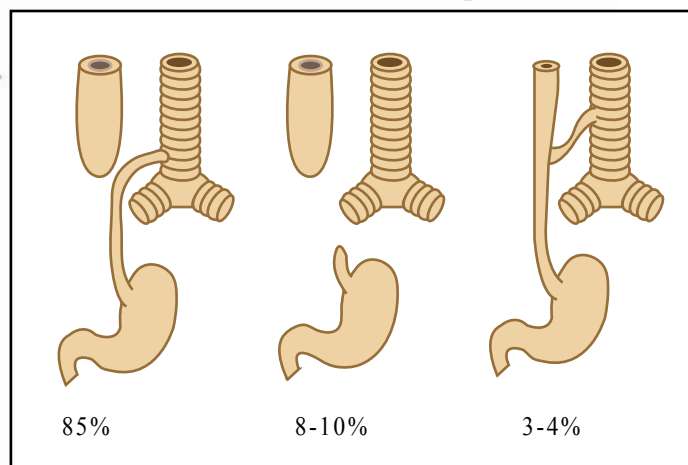
The *primitive gut* forms during the fourth week of gestation when the flat embryonic disc folds in median and horizontal planes to form a tubular structure that incorporates part of the yolk sac into the embryo. Ventral folding of the lateral sides of the embryonic disc incorporates part of the yolk sac into the embryo to form the *midgut*. At the same time, the *foregut* and the *hindgut* form as the cranial and the caudal ends of the embryo fold ventrally to incorporate additional parts of the yolk sac into the head and tail folds of the embryo. The endodermal lining of the primitive gut gives rise to the epithelial lining of most of the digestive tract and the biliary tree, as well as the parenchymas of the liver and the pancreas. The epithelium at the extreme cranial and caudal ends of the digestive tract, on the other hand, is of ectodermal origin. The muscular and connective tissue components of the digestive tract are derived from the surrounding splanchnic mesenchyme.

The *foregut* gives rise to the pharynx, lower respiratory system, esophagus, stomach, duodenum (proximal to the ampulla of Vater), liver, pancreas, and the biliary tree. The esophagus develops caudal to the primitive pharynx. Partitioning of the laryngotracheal tube from the esophagus by the *tracheoesophageal septum* results in the separation of the digestive tract from the upper respiratory tract. Errors in partitioning of these two structures result in various forms of *esophageal atresia (EA)* and *tracheoesophageal fistula (TEF)*, and are found in 1 in 3,000-5,000 live births with equal frequency among male and female infants. The most common types of defects are depicted in Figure 1 and include proximal EA with distal TEF (85% of cases), pure EA (8-10% of cases), and H-TEF (3-4% of cases). (Based on the anatomical variations shown in Figure 1,

try to postulate how a fetus with any of these

abnormalities may clinically present.) Esophageal stenosis (including esophageal web and fibromuscular stenosis) is even less common than esophageal atresia, with a frequency of in 1 in 25,000 to 50,000 live births. Esophageal stenosis can exist anywhere in the esophagus, but it is most common in the distal third. The etiology of esophageal stenosis has been debated, but it is now generally accepted that it represents a congenital lesion caused by a remnant of a perforated membrane or by incomplete recanalization of a solid core.

*Pyloric stenosis* (or congenital hypertrophic pyloric stenosis) is the most notable congenital anomaly of the stomach that is reported to occur anywhere from 1 in 1000 to 8 in 1000 live births, with a M:F ratio of 4-6:1, and a predilection for the first-born (Figure 2). Hypertrophic pyloric stenosis is a multi-factorial and progressive disease that classically presents with non-bilious projectile vomiting in the first few weeks of life.



**Figure 1.** The three most common types of EA/TEF are (A) proximal EA with distal TEF, (B) pure EA, and (C) H-TEF. (Image by MIT OCW)

Incomplete luminal recanalization is also believed to be the pathogenic mechanism for *duodenal stenosis*. Normally, during the fifth and sixth weeks of gestation the duodenal lumen is temporarily obliterated, but it is recanalized by the end of the embryonic period by a process of "vacuolization" due to degeneration of the epithelial cells. Duodenal stenosis is believed to result from incomplete recanalization of the duodenum due to defective vacuolization. Most duodenal stenoses involve the 3rd and 4th parts of the duodenum. A *functional* duodenal stenosis may also be caused by extrinsic pressure from an *annular pancreas* (see below).

Clinically, the gastric and duodenal contents are often expelled as a result of duodenal obstruction, and the vomitus typically contains bile. *Duodenal atresia* or complete occlusion of the duodenal lumen is uncommon, but it affects 20-30% of infants with Trisomy 21 and 20% of premature infants. Most atresias involve the second and third portions of the duodenum, and are located distal to the ampulla of Vater.

The *hepatic diverticulum* (or the *liver bud*), which is the origin of the liver, gallbladder, and the biliary tree, is an outgrowth of the endodermal epithelial lining of the distal foregut into the septum transversum. Growing between the layers of the *ventral mesentery*, which is derived from septum transversum, these primordial cells differentiate into the parenchyma of the liver and the lining of the biliary tree (Figure 3).

The pancreas is formed by dorsal and ventral *pancreatic buds* that originate from the endodermal lining of the foregut. The *ventral pancreatic bud* forms most of the head of the pancreas, while the *dorsal pancreatic bud* forms the remainder of the pancreas (Figure 3). In some fetuses, the duct systems of the two buds fail to fuse, and an *accessory pancreatic duct* forms.

*Annular pancreas* is a ring-like band of pancreatic tissue surrounding the second part of the duodenum. The annular pancreas probably results from the growth of a bifid ventral pancreatic bud that grows on both sides of the duodenum to fuse with the dorsal pancreatic bud. Males are affected more frequently than females. Duodenal obstruction may result in infancy, or in the adult life as a result of pancreatitis or malignancy in the annular portion.

The *midgut* gives rise to duodenum (distal to the ampulla), jejunum, cecum, appendix, ascending colon, and the right half of the transverse colon. The midgut forms a U-shaped intestinal loop that herniates into the umbilical cord during the sixth week of gestation. While in the umbilical cord, the *midgut loop* rotates 90 degrees. During the tenth week, the intestines return to the abdomen, rotating an additional 180 degrees during this process. *Omphaloceles* result from failure of the intestines to return to the abdominal cavity during the tenth week of gestation. *Umbilical hernias* result when the intestines do return to the abdominal cavity during the tenth week, but later herniate through an incompletely closed umbilicus. *Gastroschisis* is a linear defect near the median plane of the ventral abdominal wall that permits extrusion of the abdominal viscera without involving the umbilical cord. The defect usually occurs on the right, is more common in

Figure removed due to copyright reasons. Please see:

Moore, Keith L., and T. V. N. Persaud.

*The Developing Human: Clinically Oriented Embryology*

Philadelphia, PA: W.B. Saunders Company, 1998. ISBN: 0721669743.

FIGURE 3. Drawing illustrating progressive stages in development of the duodenum, liver, pancreas, and the biliary tree. (A) Four weeks, (B) and (C) five weeks, (D) six weeks (adapted from Moore, 1993).

males, and results from incomplete closure of the lateral folds during the fourth week of gestation. Remnants of the omphalomesenteric duct can be found in 1-4% of all infants, collectively making them the most common congenital anomaly of the gastrointestinal tract (Figure 4). *Meckel's diverticulum* is the most common of the omphalomesenteric duct remnants, and represents more than 80% of all these anomalies. Meckel's diverticulum typically appears as a 3- to 5-cm-long diverticulum along the antimesenteric border of the small intestine located within 40-50 cm of the ileocecal valve. The diverticulum contains all three layers of the small intestinal wall, as well as ectopic gastrointestinal tissue in more than 50% of the cases. The risk of developing clinical complications from Meckel's diverticulum is low. In one study, approximately 80% of symptomatic patients were younger than the age of 10, and almost half of these patients were younger than 2 years of age. Among Meckel's diverticula found incidentally during abdominal surgery or at autopsy, the sex ratio appears to be approximately equal. However, there is a 3-4:1 male to female ratio in clinically symptomatic patients.

Figure removed due to copyright reasons. Please see:

Moore, Keith L., and T. V. N. Persaud. *The Developing Human: Clinically Oriented Embryology*. Philadelphia, PA: W.B. Saunders Company, 1998. ISBN: 0721669743.

**FIGURE 4:** Drawing illustrating Meckel's diverticulum and other remnants of the yolk sac (adapted from Moore, 1993).

Various *anomalies of the midgut rotation* are possible, but their true incidence is not known because they represent a broad spectrum of anomalies, many of which remain asymptomatic through life. The majority of patients who develop clinical symptoms related to malrotation present within the first few weeks of life. *Stenosis or atresia* of the midgut may occur as a result of inadequate vacuolization during recanalization, or as a result of *fetal vascular accidents* and obstructive events such as *volvulus*. *Intestinal duplications* are cystic or tubular structures that result from failure of normal recanalization, giving rise to double lumen formation. Duplications lie on the mesenteric side of the bowel, and usually communicate with the intestinal lumen.

The *hindgut* gives rise to the left half of the transverse colon, the descending colon, sigmoid, rectum, and the proximal part of the anal canal (superior to the pectinate line). The caudal part of the hindgut, known as the *cloaca*, is divided by the urorectal septum into the urogenital sinus and the rectum. Most abnormalities of the hindgut are located in the anorectal region, and result from abnormal development of the urorectal septum. Anorectal malformations are present in 1 in 4,000-5,000 live births, and are often associated with urogenital or chromosomal abnormalities.

*Hirschsprung's disease* is the partial or total absence of autonomic ganglion cells in the myenteric plexus of the colon. This defect is thought to result from failure of neural crest cells to migrate into the wall of the colon during the 5th to 7th weeks of gestation. This condition classically presents as *congenital megacolon* in which the proximal portion of the colon is dilated due to narrowing and increased luminal pressure in the distal aganglionic segment. With an incidence of approximately 1 in 5,000 live births, Hirschsprung's disease is the most common cause of neonatal obstruction of the colon (one third of cases) and is 2-4 times more common in males. A positive family history is present in 6-8% of patients in general and in 50% patients with *total* colonic aganglionosis. It is estimated that up to 80% of the cases are due to autosomic dominant genetic mutations with incomplete penetrance. Hirschsprung's disease has been linked to a locus on chromosome 10q11, as well as to the mutations of the RET gene (associated with MENII) and the endothelin receptor type B gene on chromosome 13q22. In addition, anywhere from 4-13% of patients with Hirschsprung's disease are found to have Trisomy 21.

Suggested Additional Reading:

The Digestive System in: Moore, K.L. and T.V.N. Persaud, *The developing human: clinically oriented embryology*. 6th ed. 1998, Philadelphia: W. B. Saunders.